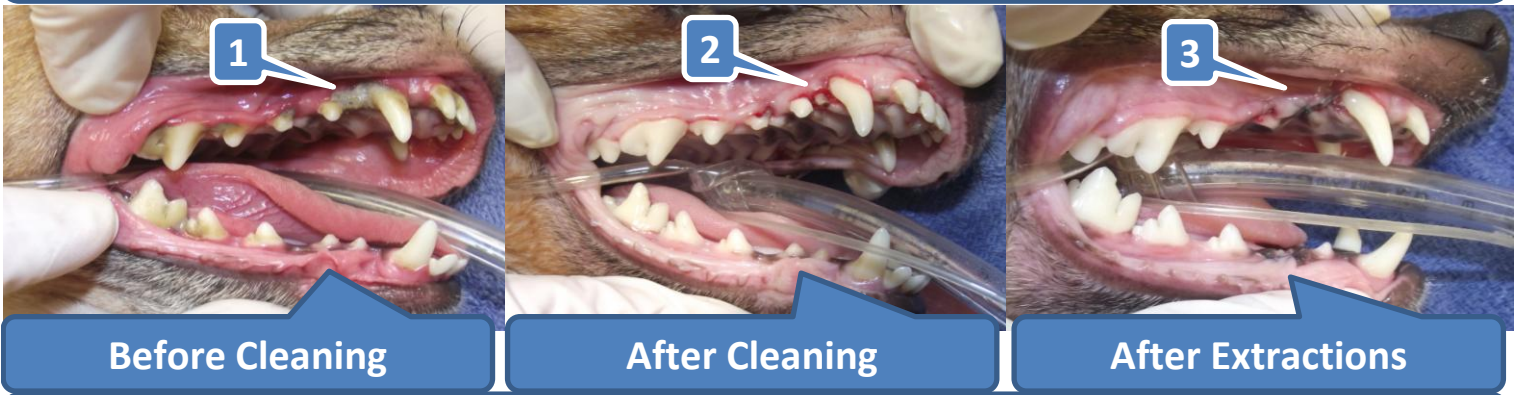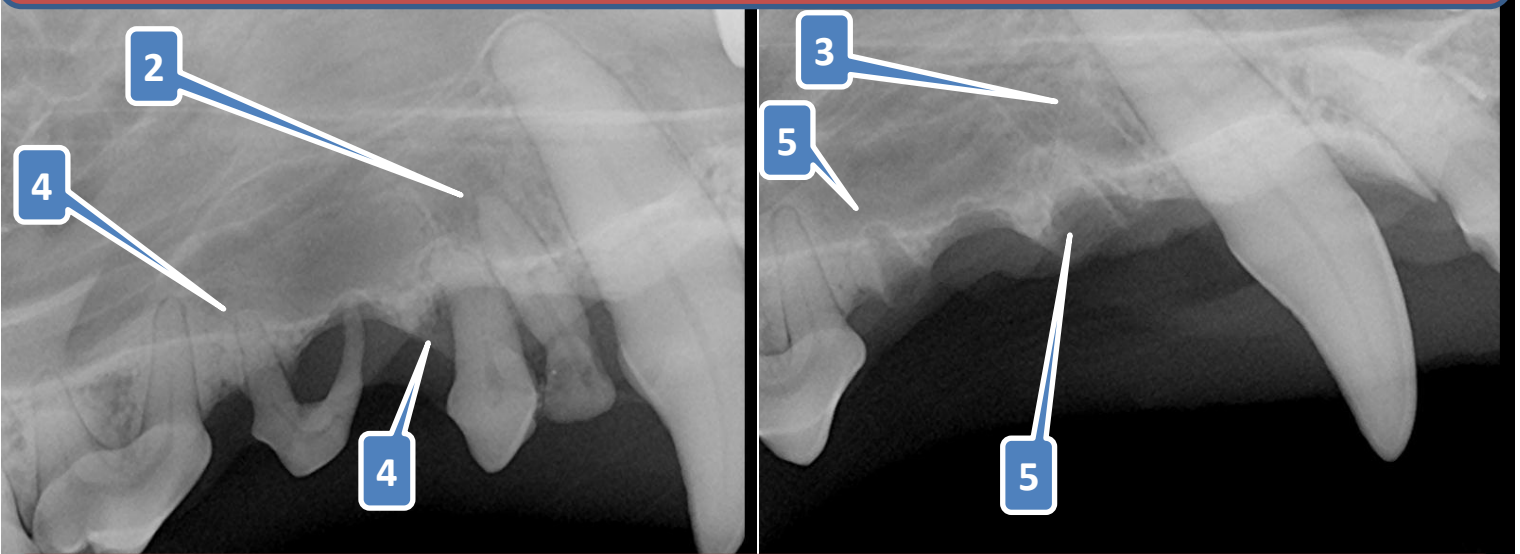


Why Does My Dog Need Dental X-rays? (pg-1)



Pictures and dental x-rays are from an 8-year old Italian Greyhound,
(right side of mouth)



Dunedin Animal Medical Center

www.DunedinAMC.com

1. Calculus* collection on a infected baby canine tooth fragment (see 1).
2. Infected baby canine tooth fragment with calculus removed before extraction (see 2).
 - a. In most dogs, baby canine teeth should 'fall out' by 20 weeks of age.
3. Infected baby canine tooth fragment has been extracted (see 3).
4. Other teeth that must be extracted (see 4).
5. Other teeth after extracted (see 5).

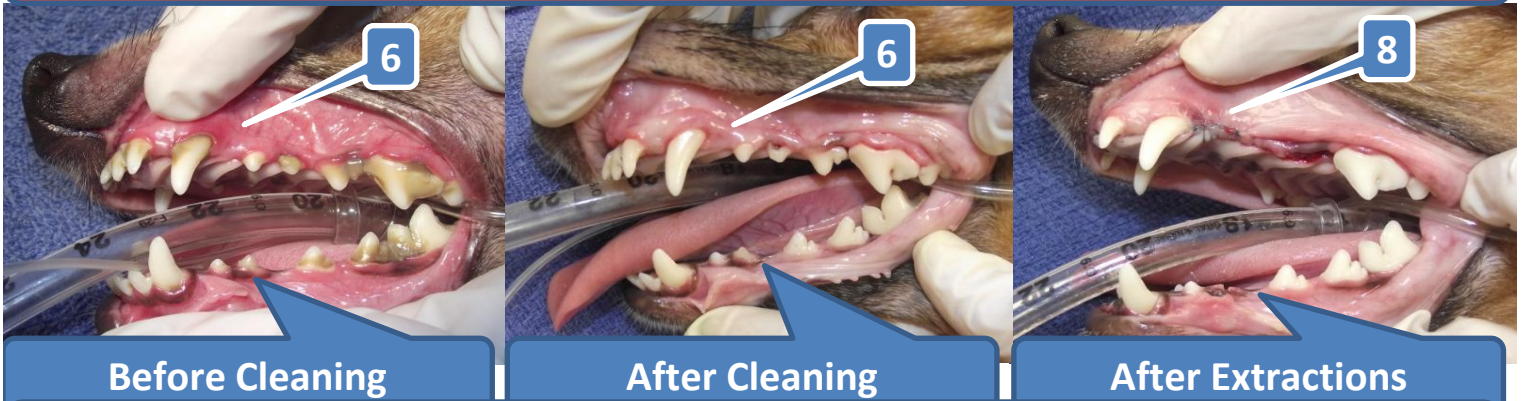NOTE:

A. After the calculus (see 1) was removed, this infected baby canine tooth fragment (see 2) could be visualized and extracted (see 3). Dental x-rays confirmed that no root fragments were left from any teeth extracted (see 3 & 5).

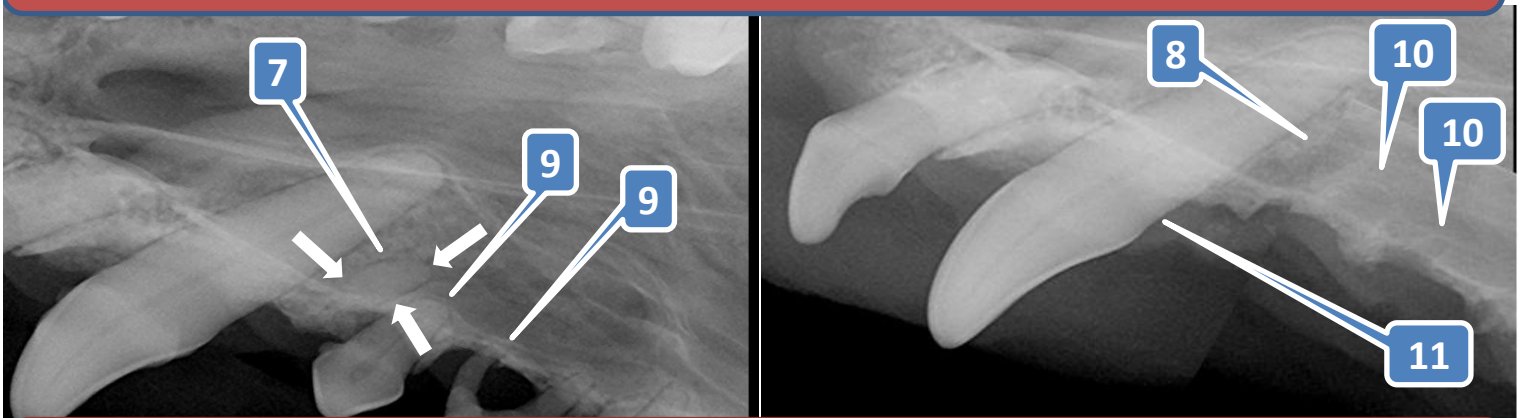
B. Not all infected teeth are found this easily (see pg-2 BELOW).

* Calculus (or Tartar) = Mineral deposits that form on teeth.

Why Does My Dog Need Dental X-rays? (pg-2)



Pictures and dental x-rays are from an 8-year old Italian Greyhound.
(left side of mouth)



Dunedin Animal Medical Center

www.DunedinAMC.com

1. Infected baby canine tooth fragment (see 6) is not visible.
2. Infected tooth is only visible with dental x-rays (see 7 and white arrows) .
 - a. In most dogs, baby canine teeth should 'fall out' by 20 weeks of age.
3. Infected baby canine tooth fragment has been extracted (see 8).
4. Other teeth that must be extracted (see 9).
5. Other teeth after extracted (see 10).
6. The Infected baby canine tooth fragment protects bacteria which resulted in Periodontitis*.
 - a. This infection was affecting the large canine tooth (see 11) and may have eventually resulted in the loss of that tooth also.

NOTE:

A. This infected root fragment *could not be visualized without the benefit of dental-x-rays*. Once identified, this painful infected tooth root was extracted (see 8).

* Periodontitis = Is a chronic infection of the gums with a loss of attachment between the tooth and the jawbone

This Is Why My Dog Does Need Dental X-rays With Every Teeth Cleaning?